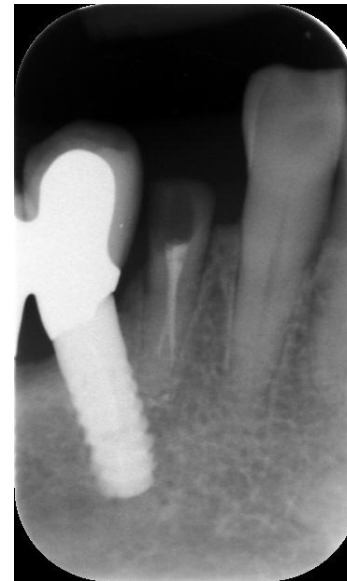
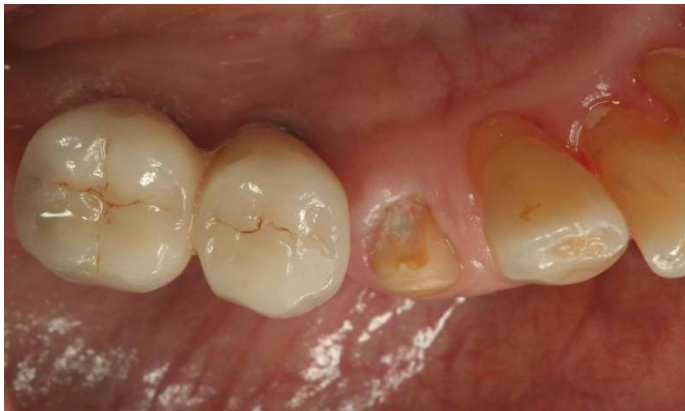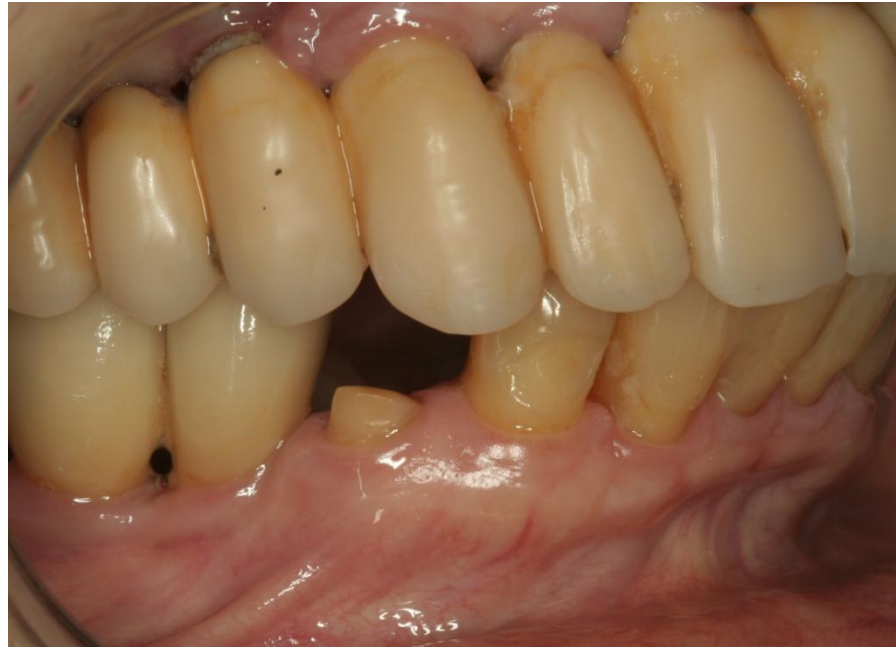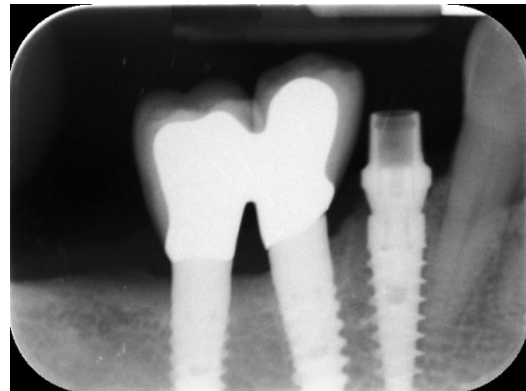
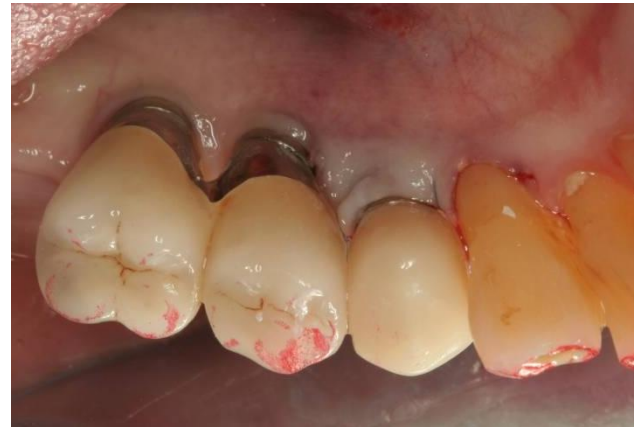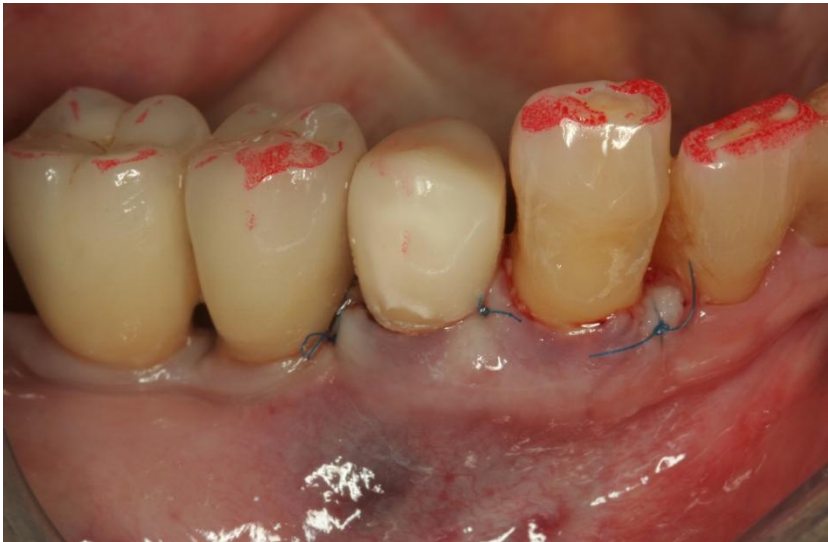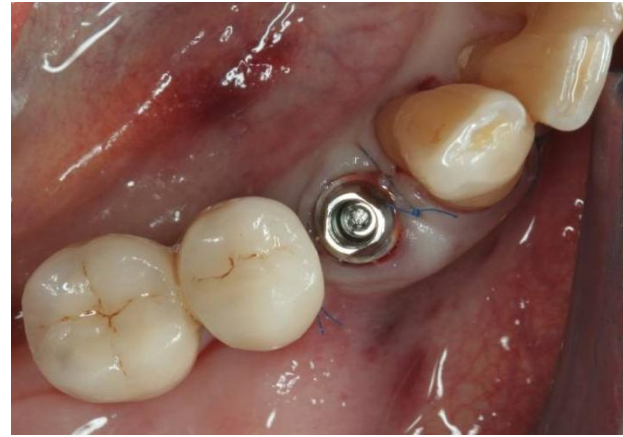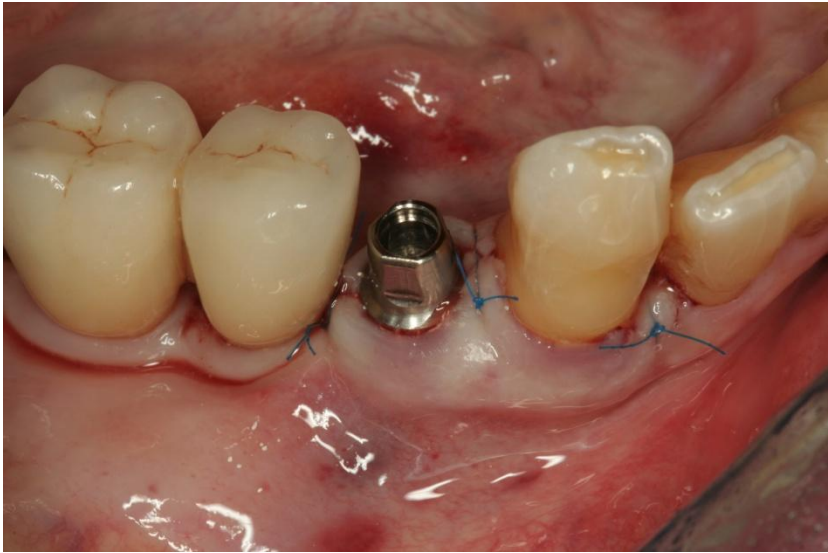
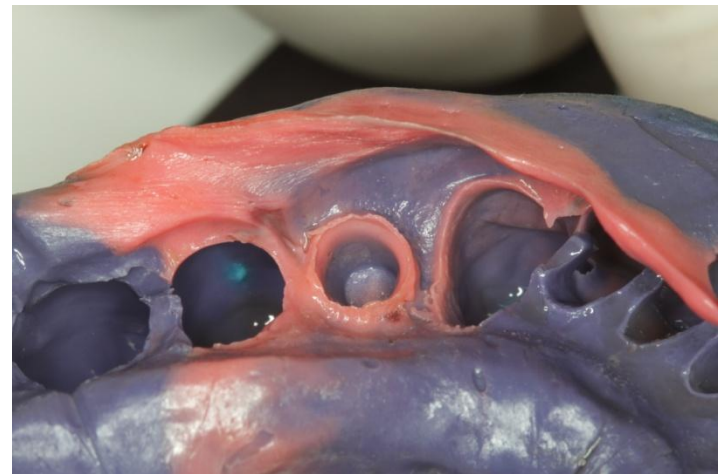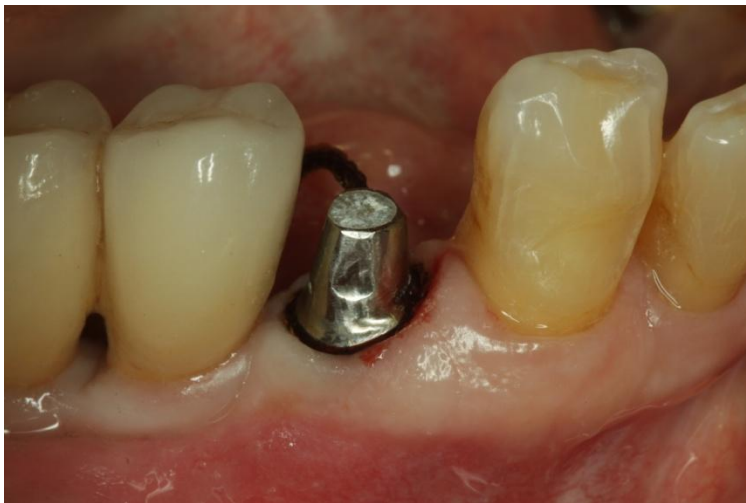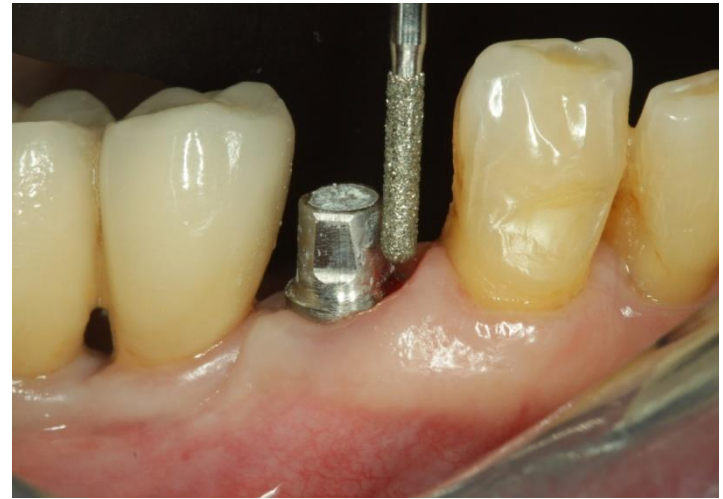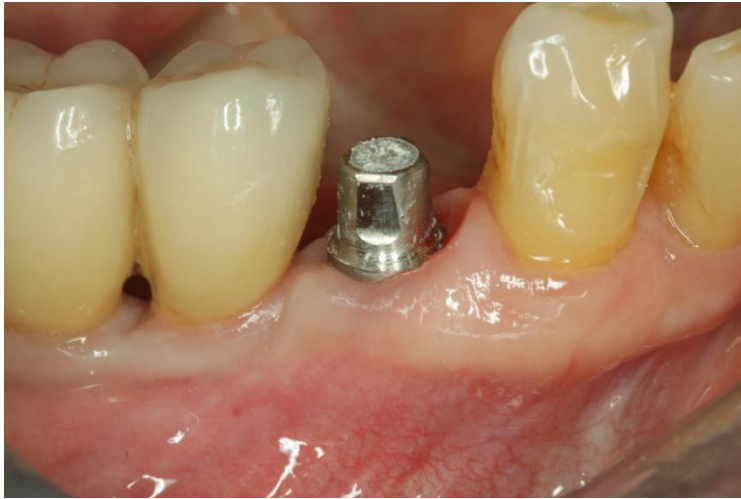


**Treatment plan:
immediate loading of a
single post-extractive
implant in site 4.4**

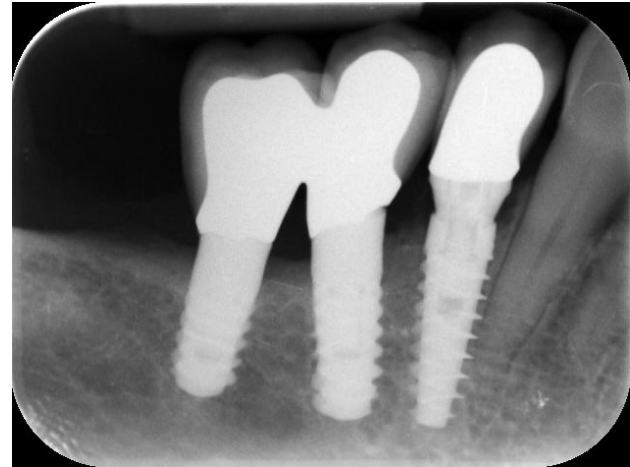
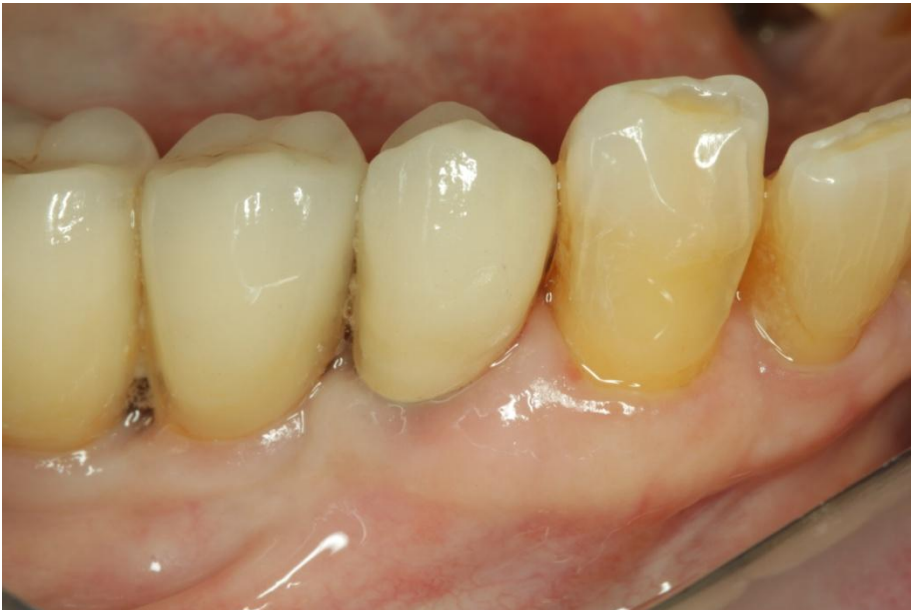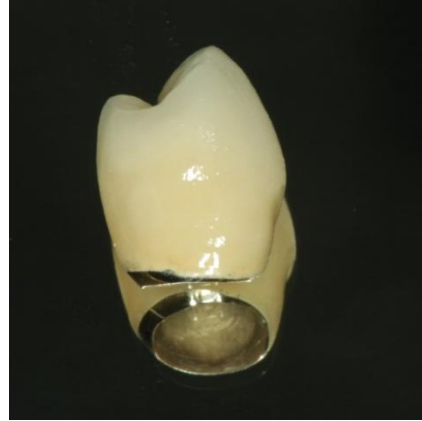

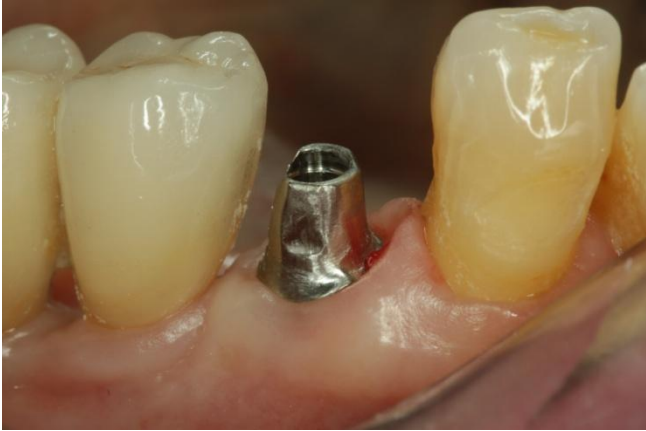


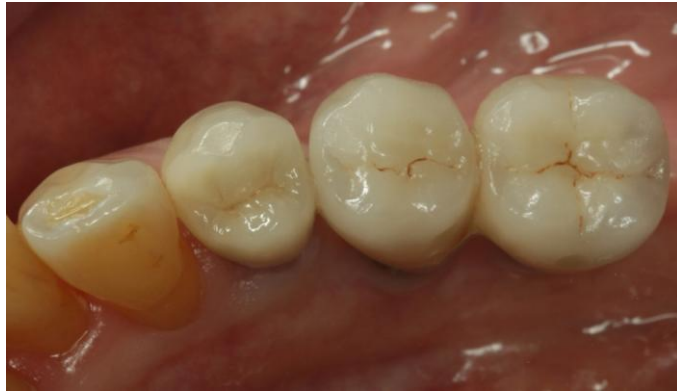After three months the final preparation of the abutment was performed and the impression was taken.



final prosthesis





After 1 year

